



Published in final edited form as:

Exp Brain Res. 2010 September ; 205(3): 405–413. doi:10.1007/s00221-010-2376-2.

Muscimol inactivation caudal to the interstitial nucleus of Cajal induces hemi-seesaw nystagmus

Vallabh E. Das,

College of Optometry, University of Houston, 505 J. Davis Armistead Building, Houston, TX 77204, USA

R. John Leigh,

Department of Neurology, Case Western Reserve University, Cleveland, OH, USA

Michelle Swann, and

Yerkes National Primate Center, Emory University, Atlanta, GA, USA

Matthew J. Thurtell

Department of Ophthalmology, Emory University, Atlanta, GA, USA

Vallabh E. Das: vdas@optometry.uh.edu

Abstract

Hemi-seesaw nystagmus (hemi-SSN) is a jerk-waveform nystagmus with conjugate torsional and disjunctive vertical components. Halmagyi et al. in *Brain* 117(Pt 4):789–803 (1994), reported hemi-SSN in patients with unilateral lesions in the vicinity of the Interstitial Nucleus of Cajal (INC) and suggested that an imbalance in projections from the vestibular nuclei to the INC was the source of the nystagmus. However, this hypothesis was called into question by Helmchen et al. in *Exp Brain Res* 119(4):436–452 (1998), who inactivated INC in monkeys with muscimol (a GABA_A agonist) and induced failure of vertical gaze-holding (neural integrator) function but not hemi-SSN. We injected 0.1–0.2 μl of 2% muscimol into the supraoculomotor area, 1–2 mm dorso-lateral to the right oculomotor nucleus and caudal to the right INC. A total of seven injections in two juvenile rhesus monkeys were performed. Hemi-SSN was noted within 5–10 min after injection for six of the injections. Around the time the hemi-SSN began, a small skew deviation also developed. However, there was no limitation of horizontal or vertical eye movements, suggesting that the nearby oculomotor nucleus was not initially compromised. Limitations in eye movement range developed about ½–1 h following the injections. Clinical signs that were observed after the animal was released to his cage included a moderate to marked head tilt toward the left (contralesional) side, consistent with an ocular tilt reaction. We conclude that hemi-SSN can be caused by lesions just caudal to the INC, whereas lesions of the INC itself cause down-beat nystagmus and vertical gaze-holding failure, as demonstrated by Helmchen et al. Combined deficits may be encountered with lesions that involve several midbrain structures.

Keywords

Hemi-seesaw nystagmus; Rhesus; Muscimol; Oculomotor

Introduction

In 1975, Westheimer and Blair reported that an ipsilesional ocular tilt reaction (OTR) developed when they electrically stimulated in the region of the interstitial nucleus of Cajal (INC) in macaque monkeys (Westheimer and Blair 1975). The OTR they induced consisted of extorsion and depression of the eye on the stimulated side, intorsion and elevation of the other eye, and head tilt toward the stimulated side (Westheimer and Blair 1975; Leigh and Zee 2006). Deep brain stimulation in the region of the INC in humans has also been reported to produce an ipsilesional OTR (Lueck et al. 1991). Conversely, destructive lesions in the region of the INC in humans are reported to cause a contralesional OTR, with tonic intorsion and elevation of the eye ipsilateral to the lesion, extorsion, and depression of the contralateral eye, and a head tilt away from the side of the lesion (Brandt and Dieterich 1987; Halmagyi et al. 1990).

A phenomenon related to the OTR is jerk-seesaw or hemi-seesaw nystagmus (hemi-SSN), in which each slow phase is in the direction of tonic deviation of the OTR, with corrective quick phases in the opposite direction (Fig. 1). Affected individuals often have an associated contralesional head tilt. Halmagyi et al. reported hemi-SSN in three patients with unilateral lesions in the vicinity of the INC and suggested that an imbalance in projections from the vestibular nuclei to the INC was the source of the nystagmus (Halmagyi et al. 1994). Confirmation of this hypothesis would come from inducing hemi-SSN by inactivation of the INC in non-human primates; however, muscimol (a GABA_A agonist) failed to induce hemi-SSN when injected into, or rostral to, the INC of the macaque (Helmchen et al. 1998; Rambold et al. 1999). Instead, unilateral or bilateral inactivation of the INC resulted in failure of vertical gaze holding (leaky neural integrator), torsional and down-beat nystagmus, but not hemi-SSN. Thus, there appeared to be disagreement between clinical reports and experimental studies in macaque as to what midbrain lesion caused hemi-SSN, and whether INC was involved.

During the course of experiments in strabismic non-human primates, aimed at inactivation of near-response neurons in the midbrain (just caudal to the INC), we serendipitously induced hemi-SSN with muscimol micro-injections, providing information that could help resolve this issue. Some of these data have been presented in abstract form (Das et al. 2009).

Methods

Experimental subjects

Data were collected from two juvenile rhesus monkeys (ages 5 and 7 years; weights 7 and 10 kg) for these experiments. The animals used in this study were part of other studies examining mechanisms of strabismus and were exotropic. We have previously described eye alignment and eye movement properties of similar strabismic animals in detail (Das et al. 2004, 2005; Das and Mustari 2007; Fu et al. 2007; Das 2009). Although the animals showed certain disorders of binocular coordination, such as cross-axis eye movements associated with 'A' and 'V' patterns of strabismus and dissociated vertical deviation (DVD), none of them had hemi-SSN prior to the muscimol inactivation experiments. Therefore, their eye movements were considered normal for the purposes of this study. During monocular viewing, a low-grade latent nystagmus (<2°/s) was observed in the two animals that participated in this study.

Surgical procedures and eye movement measurements

Sterile surgical procedures performed under aseptic conditions using isoflurane anesthesia (1.25–2.5%) were used to stereotaxically implant a head stabilization post and a neurophysiological recording chamber (Das and Mustari 2007). The implanted chamber was inclined at an angle of 20° to the sagittal plane and was positioned antero-posteriorly and medio-

laterally such that it allowed access to both oculomotor nuclei and surrounding areas. During the same procedure, a scleral search coil was implanted in one eye (Judge et al. 1980). Later, in a second surgery, a scleral search coil was implanted in the other eye. All procedures were performed in strict compliance with National Institutes of Health and Association for Research in Vision and Ophthalmology guidelines, and the protocols were reviewed and approved by the Institutional Animal Care and Use Committee.

Binocular eye position was measured in two dimensions (horizontal and vertical) using the magnetic search coil technique (Primelec Industries, Regensdorf, Switzerland). Calibration of the eye coil signal was achieved by giving the monkey a small amount of juice or other reward when eye position was within a small region ($\pm 2^\circ$ window) surrounding a 0.25° target spot that was rear projected onto a tangent screen 60 cm away from the animal. All stimuli were under computer control. Calibration of each eye was performed independently during monocular viewing.

Experimental paradigms, data collection, and analysis

These experiments describe effects of muscimol inactivation of structures in the vicinity of the right INC and oculomotor nucleus (OMN). We first located the OMN by identifying its characteristic burst-tonic responses during saccadic eye movements in the preferred direction. We also located the midbrain near-response region by identifying cells that responded to changes in vergence angle (changes in eye misalignment in the animals in this study), but did not respond to changes in conjugate eye position (Mays 1984); the near-response cells are scattered approximately 2 mm lateral and dorsal to the caudal third of the OMN. Since the electrode penetrations were at an angle of 20° to the sagittal plane, we encountered near-response cells on the same electrode track as the motoneurons, but at a depth approximately 2 mm above the motoneurons. The INC is approximately in the same mediolateral and dorsoventral location as the near-response area, but lies near the rostral (rather than caudal) third of the OMN and extends further rostrally in the brainstem (Buttner-Ennever 1988). The target location for the muscimol injections was the midbrain near-response area (lateral and dorsal to the OMN; caudal to the INC).

In the muscimol injection experiments, we used a custom-built small-diameter (36 Ga stainless steel tubing, Small Parts Inc) micro-injection system. During injection experiments, the injection micropipette was mounted on the same microdrive used for electrode recording, and the pipette tip was positioned at the depth where near-response cells were recorded. 0.1–0.2 μ l of muscimol (conc. 2%; Sigma–Aldrich) was delivered at the desired depth using a picoliter pump (WPI-PV830), connected to the micropipette, to provide timed air pressure pulses allowing for a gradual delivery of muscimol over several (5–10) minutes (Ono et al. 2003).

Binocular eye and target position feedback signals were processed with anti-aliasing filters at 400 Hz using six-pole Butterworth filters before digitization at 1 kHz with 12-bit precision (Labview Software and PCI-6025E DAQ board—National Instruments, Austin, TX). In each experimental session, data were collected immediately prior to and following the injection of muscimol. Fixation, saccade, and smooth-pursuit testing during monocular viewing conditions were performed to identify eye movement abnormalities, including nystagmus. Data analysis involved calculating the frequency, amplitude, slow-phase velocity, and direction of the nystagmus in the horizontal and vertical planes.

Histology

Several weeks after the muscimol injections, an electrolytic lesion was placed near the site of the injections (20 μ A for 20 s). A second electrolytic lesion was placed 2 mm above the first lesion, to allow for accurate histological scaling. Three weeks after placing the electrolytic

lesions, the animals were perfused, and their brains removed for histology. For histological evaluation of the lesion and recording sites, the brain was blocked, and 50- μm -thick coronal plane sections were cut stereotaxically and stained for Nissl substance.

Results

Four muscimol inactivation experiments were performed in monkey M1, and three were performed in monkey M2. Of these, three injections in M1 and all three injections in M2 elicited hemi-SSN. In the one injection that did not produce hemi-SSN, we also did not observe any other form of horizontal or vertical nystagmus. Injection experiments in each animal were performed approximately a week apart, giving the animal ample time to recover prior to the next injection.

Vertical eye movement deficits following injection of muscimol

Representative records of hemi-SSN induced by muscimol injection in monkey M1 are shown in Fig. 2. Horizontal eye movements are shown in panels a and b, and vertical eye movements in panels c and d. In all cases, the monkey was rewarded for attempting to fixate the stationary target. Prior to injection (a and c), a low-amplitude, left-beating, latent nystagmus was evident. Following the injection, M1 developed a brisk disjunctive jerk-waveform vertical nystagmus (hemi-SSN); his horizontal latent nystagmus was slightly increased. Figure 3 shows the hemi-SSN in M2 following muscimol injection. The frequency of the nystagmus across all injections ranged approximately 1–3 Hz in monkey M1 and 2–3 Hz in monkey M2. The amplitude of slow phases ranged approximately 3–8° in M1 and 1–2° in M2. In both M1 and M2, the slow phases were upward in the right eye and downward in the left eye. In M1, the average slow-phase velocities ranged 2.34–9.89°/s in the right eye and 1.07–4.88°/s in the left. In M2, the average slow-phase velocities ranged from 1.04 to 2.24°/s in the right eye and 0.88–1.97°/s in the left.

The hemi-SSN was usually the first eye movement sign that developed following the injection of muscimol, and usually occurred within 5–10 min after the injection. In addition to hemi-SSN, a vertical eye misalignment (skew deviation) also developed, in which the right eye was higher than the left; this deviation corresponded to that seen with the slow phases of hemi-SSN (Fig. 1) and is consistent with a lesion in the region of the right INC. The skew deviation was superimposed on a pre-injection vertical misalignment (DVD). The pre-injection DVD, as estimated during central fixation, was approximately 4–7° in M1 and 2–4° in M2. The magnitude of the skew deviation following injection of muscimol ranged an additional 3–5° in M1 and 1–6° in M2.

At the time the hemi-SSN was first observed, there was little limitation in vertical eye movements, suggesting that vertical muscle subdivisions of the OMN were not compromised. Figure 4 shows that animal M1 was generating appropriately sized vertical saccadic eye movements in the presence of the hemi-SSN. Limitation of vertical eye movements, in which the animal was not able to make vertical eye movements across the horizontal meridian, was observed later (approximately ½–1 h after injection in most of the injections). In most injections (5/6), the vertical deficit usually consisted of an inability to look below the horizontal meridian, with greater deficits in the right eye compared to the left. In one experiment, the left eye showed a more pronounced deficit, and there was an inability to look above rather than below the horizontal meridian. These limitations could be due to partial inactivation of one or more vertical muscle subdivisions in the right OMN, or a pronounced skew deviation. Data collection was usually stopped when the gaze limitations became apparent.

Also illustrated in Fig. 4 is the effect of horizontal and vertical gaze position on the amplitude and frequency of the hemi-SSN. The frequency of hemi-SSN generally increased, and vertical

disconjugacy was more evident, in upgaze; however, this was not consistently observed in all of the injection experiments in the two monkeys studied. Little change in the frequency of the hemi-SSN was observed with changes in horizontal gaze position. No evidence of vertical gaze-holding failure other than the hemi-SSN itself was noted immediately after the injection.

Horizontal eye movement deficits following injection of muscimol

A smaller horizontal nystagmus, synchronized with the vertical nystagmus, was generally observed following the muscimol injections; the properties of the horizontal component were variable. The nystagmus was sometimes conjugate (see Fig. 2), but on other occasions it was convergent (see Fig. 3). The amplitude of the horizontal slow phases was approximately 1° in M1 and $<1^\circ$ in M2.

Figure 4 shows that there was no limitation of horizontal eye movements during the initial period following muscimol injection (at the time when hemi-SSN was observed) in M1. Thus, the animals were able to make normal horizontal smooth-pursuit and saccadic eye movements, as in the pre-injection state, suggesting that the muscimol did not initially inactivate the medial rectus motoneurons in the OMN. However, in 3/6 injections, approximately $\frac{1}{2}$ –1 h after the initial effects, there was evidence that the spread of muscimol compromised the medial rectus subdivisions of the right oculomotor nucleus; we often observed adduction weakness, with the eye being unable to cross the midline. This outcome is consistent with spread of muscimol following a unilateral injection on the right side, lateral and dorsal to the oculomotor nucleus. No significant limitation of horizontal eye movements developed with the other three injections.

Torsional eye movement deficits following injection of muscimol

Although torsional nystagmus is an important component of hemi-SSN (Fig. 1), we were unable to characterize this aspect of the disorder as we did not use three-dimensional search coils to measure torsional eye movements in these experiments. However, an obvious conjugate torsional component to the hemi-SSN was observed following each of the injections that elicited it.

Clinical observations

At the end of the experimental session (approximately 1–2 h after the injection), we were also able to make the following clinical observations in the animals. Following each injection, there was a mild to marked contralesional head tilt toward the left; this leftward head tilt is consistent with a contralesional OTR. In addition, we observed a contralesional (left) eyelid ptosis in 6/7 injection experiments. Bilateral ptosis was observed in the other experiment, and, incidentally, this was also the only injection that did not produce hemi-SSN. These clinical signs improved significantly over the following hours and were not apparent the following day.

Histology

Two electrolytic lesions were placed near the injection site (see “Methods”), and histological evaluation was performed to ascertain which structures might have been inactivated by the muscimol. Figure 5 shows the reconstructed electrode/pipette tracks and also locations of the electrolytic lesions in monkey M1. The histology figure shows three coronal sections, each about 1.5 mm apart. Parts of the OMN can be seen in all sections from the caudal end of the OMN in the most caudal section in the figure. The INC is visible in the most rostral section in the figure. Since the electrolytic lesions were not placed in the same penetration as the muscimol injection, there might be some mismatch between the injection and electrolytic lesion locations. However, the location of the electrolytic lesions and electrode/pipette tracks suggest that the muscimol was probably injected about 2 mm caudal to the INC (probably in the vicinity

of the caudal two sections shown in the figure), and probably just lateral to the peri-aqueductal gray and lateral/dorsal to the OMN nucleus.

Discussion

Our main finding is that injection of muscimol just caudal to the INC consistently induced hemi-SSN. In the present study, the area inactivated was lateral and dorsal to the right OMN and caudal to the INC; this locus appears to correspond with the area stimulated electrically by Westheimer and Blair in 1975. We base this estimate on several factors. Neuronal recordings indicated that motoneurons of the OMN were located about 2 mm deeper to the injection site, while histological reconstruction of the recording and injection sites suggested that the injections were delivered caudal to the INC. The clinical observations of a leftward head tilt and torsional nystagmus could be due to eventual involvement of the right INC (Helmchen et al. 1998), whereas the ptosis suggests involvement of the central caudal nucleus (CCN), which lies immediately dorsal to the caudal aspect of the OMN (Porter et al. 1989), or the M-group neurons which lie rostral to the INC (Horn et al. 2000). As these clinical signs were observed 1–2 h after the injection, the initial area inactivated was probably just caudal to the INC.

Our experiments do not implicate the INC in the generation of hemi-SSN. Vertical gaze-holding failure is a marker of INC inactivation (Helmchen et al. 1998) but, when hemi-SSN was first observed in our monkeys (see Fig. 4b), the vertical gaze-holding deficit was small (although it remains possible that this may simply be because we injected a rather small volume of muscimol adjacent to and not directly into the INC). Thus, it appears that lesions caudal to, but probably not involving, the INC lead to hemi-SSN. However, involvement of just the most caudal aspect of the INC cannot be ruled out. In interpreting the effects of clinical reports and the data presented in this study, it is important to note that the midbrain contains several visual-oculomotor structures lying within a few mm of one another, which could have fallen within the sphere of influence of our injected muscimol (Arikan et al. 2002). These include the OMN, INC, CCN, and the M-group neurons, the nucleus of the posterior commissure [also thought to be involved in the neural integration of vertical eye movements (Moschovakis et al. 1996)], the midbrain near-response region (Mays 1984), and parts of the central mesencephalic reticular formation (cMRF). Furthermore, lesions in the ventral-caudal region of the MRF are reported to cause contralateral head tilt (Waitzman et al. 2000). Since these midbrain structures lie in close proximity, clinical lesions causing hemi-SSN might well also affect adjacent structures, including the INC. This view would account for the apparent discrepancy of the predictions of Halmagyi et al. (1994), which were based on large clinical lesions (hemorrhages), and the observed effects of selective muscimol inactivation of the INC in macaque (Helmchen et al. 1998; Rambold et al. 1999) and our muscimol injections, which were probably about 1–2 mm more caudal.

Possible influence of strabismus on present findings

Some caution is required in interpreting our present findings, because the animals in this study were reared with strabismus, showed DVD (Das et al. 2005), and may also have had some torsional misalignment as indicated by the presence of A/V pattern strabismus (Guyton and Weingarten 1994). These factors, which could potentially pre-dispose the system toward generation of an OTR, could have contributed toward generation of hemi-SSN upon injection of muscimol into the INC region (Guyton et al. 1998; Brodsky and Donahue 2001). At least one of the patients described by Halmagyi et al. appears to have had a long-standing vertical eye misalignment prior to development of hemi-SSN. Thus, it would be important to repeat this study in normal monkeys to verify that the observation of hemi-SSN is a function of the location of the injection and not the presence of a pre-existing strabismus or DVD.

Hypothetical mechanisms for hemi-SSN

If hemi-SSN is caused by lesions caudal to the INC, how might this arise? A modern view of the INC, which draws on anatomical, histochemical, and electrophysiological studies (Moschovakis et al. 1996; Helmchen et al. 1998; Horn 2006) suggests that the INC serves more than one function. First, burst-tonic neurons appear to contribute to velocity-to-position integration for vertical premotor signals, especially via their projections across the posterior commissure to the contralateral INC. Thus, inactivation of the posterior commissure (Partsalis et al. 1994), or bilateral inactivation of the INC (Helmchen et al. 1998), impairs the integration of vertical eye movements, and unilateral inactivation (Crawford et al. 1991) impairs gaze-holding following saccades. Second, many neurons in the INC are saccadic bursters that project to the ipsilateral rostral interstitial nucleus of the medial longitudinal fasciculus (riMLF) and might contribute to feedback control of vertical saccades (Horn et al. 2003). Third, the INC projects not just to structures concerned with eye movements, but also to brainstem nuclei important for head movements (Kokkoroyannis et al. 1996), such as the pontine nucleus gigantocellularis, and even to segments of the cervical spinal cord that innervate neck muscles. It is this latter function of the INC that seems important for the generation of the head tilt seen with the OTR. As pointed out in the Introduction, the slow-phase component of hemi-SSN is identical to the deviation seen with the OTR (Fig. 1). Acutely, the head tilt and skew deviation are the most striking clinical findings in patients with an OTR, but when measurements are made, nystagmus is often detected as well (Averbuch-Heller et al. 1997). Some patients might present with hemi-SSN without an associated OTR. Furthermore, hemi-SSN has been reported in patients with lower brainstem lesions, such as in the medial medulla and MLF (Choi et al. 2004), and with congenital hindbrain anomalies, such as the Chiari malformation (Zimmerman et al. 1986). Common to each of these presentations may be an imbalance of central otolithic projections (Halmagyi et al. 1994). Halmagyi and colleagues also speculated that the oppositely directed vertical quick phases in each eye could be due to relative differences in strengths of the cyclo-vertical muscles. Thus, equal hyper-activation of the superior rectus and superior oblique of one eye and inferior rectus and inferior oblique of the other eye would produce a torsional nystagmus consistent with hemi-SSN, but no vertical component. However, if there was an additional difference in relative strength of the rectus and oblique muscle activations of an eye, then oppositely directed vertical quick phases would be generated as well. Of course, these muscle innervation changes would have to be implemented such that the quick phases are indeed resetting. Such a mechanism might be similar to the “brainstem ocular motor routine” (OTR) first postulated by Westheimer and Blair, but concern “resetting” quick phases (and riMLF) rather than the slow phases. Probably distinct from hemi-SSN, however, is pendular SSN, which consists of sinusoidal seesaw oscillations without quick phases; this form of SSN occurs most commonly in association with lesions involving the optic chiasm. Pendular seesaw nystagmus might result from loss of visual inputs that are important for “calibration” of the mechanism that generates eye movements to compensate for head rotations in roll (Leigh and Zee 2006).

In conclusion, our results indicate that hemi-SSN can be produced by lesions caudal to the INC. Further experimental inactivation studies in normal macaques and clinical observations in patients with discrete midbrain lesions are needed to confirm this hypothesis.

Acknowledgments

We wish to thank Dr. Yoland Smith, Yerkes National Primate Center, for processing the brain tissue for histology. This work was supported by NIH grant RO1-EY015312 (VED); UHCO core grant P30 EY 07551 (VED) and Yerkes base grant RR00165 (VED). RJL was supported by NIH R01-EY06717, Department of Veterans Affairs, and Evonor Armington Fund.

References

- Arikan R, Blake NM, Erinjeri JP, Woolsey TA, Giraud L, Highstein SM. A method to measure the effective spread of focally injected muscimol into the central nervous system with electro-physiology and light microscopy. *J Neurosci Methods* 2002;118(1):51–57. [PubMed: 12191757]
- Averbuch-Heller L, Rottach KG, Zivotofsky AZ, Suarez JI, Pettee AD, Remler BF, Leigh RJ. Torsional eye movements in patients with skew deviation and spasmodic torticollis: responses to static and dynamic head roll. *Neurology* 1997;48(2):506–514. [PubMed: 9040747]
- Brandt T, Dieterich M. Pathological eye-head coordination in roll: tonic ocular tilt reaction in mesencephalic and medullary lesions. *Brain* 1987;110(Pt 3):649–666. [PubMed: 3495315]
- Brodsky MC, Donahue SP. Primary oblique muscle overaction: the brain throws a wild pitch. *Arch Ophthalmol* 2001;119(9):1307–1314. [PubMed: 11545636]
- Buttner-Ennever, JA. *Neuroanatomy of the oculomotor system*. Elsevier; Amsterdam: 1988.
- Choi KD, Jung DS, Park KP, Jo JW, Kim JS. Bowtie and upbeat nystagmus evolving into hemi-seesaw nystagmus in medial medullary infarction: possible anatomic mechanisms. *Neurology* 2004;62(4):663–665. [PubMed: 14981194]
- Crawford JD, Cadera W, Vilis T. Generation of torsional and vertical eye position signals by the interstitial nucleus of Cajal. *Science* 1991;252(5012):1551–1553. [PubMed: 2047862]
- Das VE. Alternating fixation and saccade behavior in nonhuman primates with alternating occlusion-induced exotropia. *Invest Ophthalmol Vis Sci* 2009;50(8):3703–3710. [PubMed: 19279316]
- Das VE, Mustari MJ. Correlation of cross-axis eye movements and motoneuron activity in non-human primates with “A” pattern strabismus. *Invest Ophthalmol Vis Sci* 2007;48(2):665–674. [PubMed: 17251464]
- Das VE, Ono S, Tusa RJ, Mustari MJ. Conjugate adaptation of saccadic gain in non-human primates with strabismus. *J Neurophysiol* 2004;91(2):1078–1084. [PubMed: 14586028]
- Das VE, Fu LN, Mustari MJ, Tusa RJ. Incomitance in monkeys with strabismus. *Strabismus* 2005;13(1):33–41. [PubMed: 15824015]
- Das VE, Swann M, Thurtell M, Leigh RJ. Muscimol micro-injections in the vicinity of the interstitial nucleus of Cajal induces hemi-seesaw nystagmus. *Soc Neurosci Abstr* 2009;356:23.
- Fu L, Tusa RJ, Mustari MJ, Das VE. Horizontal saccade disconjugacy in strabismic monkeys. *Invest Ophthalmol Vis Sci* 2007;48(7):3107–3114. [PubMed: 17591880]
- Guyton DL, Weingarten PE. Sensory torsion as the cause of primary oblique muscle overaction/underaction and A- and V-pattern strabismus. *Binocul Vis Strabismus Q* 1994;9(3):209–236.
- Guyton DL, Cheeseman EW Jr, Ellis FJ, Straumann D, Zee DS. Dissociated vertical deviation: an exaggerated normal eye movement used to damp cyclovertical latent nystagmus. *Trans Am Ophthalmol Soc* 1998;96:389–424. discussion 424–429. [PubMed: 10360299]
- Halmagyi GM, Brandt T, Dieterich M, Curthoys IS, Stark RJ, Hoyt WF. Tonic contraversive ocular tilt reaction due to unilateral meso-diencephalic lesion. *Neurology* 1990;40(10):1503–1509. [PubMed: 2215939]
- Halmagyi GM, Aw ST, Dehaene I, Curthoys IS, Todd MJ. Jerk-waveform see-saw nystagmus due to unilateral meso-diencephalic lesion. *Brain* 1994;117(Pt 4):789–803. [PubMed: 7922466]
- Helmchen C, Rambold H, Fuhry L, Buttner U. Deficits in vertical and torsional eye movements after uni- and bilateral muscimol inactivation of the interstitial nucleus of Cajal of the alert monkey. *Exp Brain Res* 1998;119(4):436–452. [PubMed: 9588778]
- Horn AK. The reticular formation. *Prog Brain Res* 2006;151:127–155. [PubMed: 16221588]
- Horn AK, Buttner-Ennever JA, Gayde M, Messoudi A. Neuroanatomical identification of mesencephalic premotor neurons coordinating eyelid with upgaze in the monkey and man. *J Comp Neurol* 2000;420(1):19–34. [PubMed: 10745217]
- Horn AK, Helmchen C, Wahle P. GABAergic neurons in the rostral mesencephalon of the macaque monkey that control vertical eye movements. *Ann NY Acad Sci* 2003;1004:19–28. [PubMed: 14662444]
- Judge SJ, Richmond BJ, Chu FC. Implantation of magnetic search coils for measurement of eye position: an improved method. *Vis Res* 1980;20:535–538. [PubMed: 6776685]

- Kokkoroyannis T, Scudder CA, Balaban CD, Highstein SM, Moschovakis AK. Anatomy and physiology of the primate interstitial nucleus of Cajal I. efferent projections. *J Neurophysiol* 1996;75(2):725–739. [PubMed: 8714648]
- Leigh, R.J.; Zee, D.S. *The neurology of eye movements*. Oxford University Press; New York: 2006.
- Lueck CJ, Hamlyn P, Crawford TJ, Levy IS, Brindley GS, Watkins ES, Kennard C. A case of ocular tilt reaction and torsional nystagmus due to direct stimulation of the midbrain in man. *Brain* 1991;114 (Pt 5):2069–2079. [PubMed: 1933234]
- Mays LE. Neural control of vergence eye movements: convergence and divergence neurons in midbrain. *J Neurophysiol* 1984;51(5):1091–1108. [PubMed: 6726313]
- Moschovakis AK, Scudder CA, Highstein SM. The microscopic anatomy and physiology of the mammalian saccadic system. *Prog Neurobiol* 1996;50(2–3):133–254. [PubMed: 8971981]
- Ono S, Das VE, Mustari MJ. Role of the dorsolateral pontine nucleus in short-term adaptation of the horizontal vestibuloocular reflex. *J Neurophysiol* 2003;89(5):2879–2885. [PubMed: 12740419]
- Partsalis AM, Highstein SM, Moschovakis AK. Lesions of the posterior commissure disable the vertical neural integrator of the primate oculomotor system. *J Neurophysiol* 1994;71(6):2582–2585. [PubMed: 7931540]
- Porter JD, Burns LA, May PJ. Morphological substrate for eyelid movements: innervation and structure of primate levator palpebrae superioris and orbicularis oculi muscles. *J Comp Neurol* 1989;287(1): 64–81. [PubMed: 2477400]
- Rambold H, Helmchen C, Buttner U. Unilateral muscimol inactivations of the interstitial nucleus of Cajal in the alert rhesus monkey do not elicit seesaw nystagmus. *Neurosci Lett* 1999;272(2):75–78. [PubMed: 10507545]
- Waitzman DM, Silakov VL, DePalma-Bowles S, Ayers AS. Effects of reversible inactivation of the primate mesencephalic reticular formation. I. Hypermetric goal-directed saccades. *J Neurophysiol* 2000;83(4):2260–2284. [PubMed: 10758133]
- Westheimer G, Blair SM. The ocular tilt reaction—a brainstem oculomotor routine. *Invest Ophthalmol* 1975;14(11):833–839. [PubMed: 810454]
- Zimmerman CF, Roach ES, Troost BT. See-saw nystagmus associated with Chiari malformation. *Arch Neurol* 1986;43(3):299–300. [PubMed: 3947282]

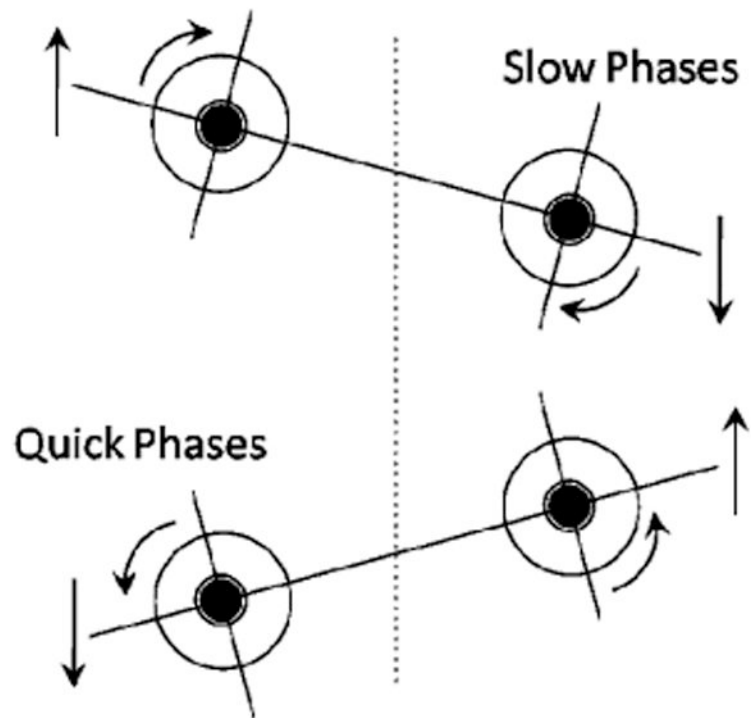


Fig. 1. Schematic representation showing the disjunctive vertical and conjugate torsional eye movements of hemi-SSN. This pattern corresponds to what Halmagyi et al. (1994) postulated would result from a lesion in the vicinity of the right INC. It is also the pattern of hemi-SSN observed in this study following muscimol inactivation of the right INC

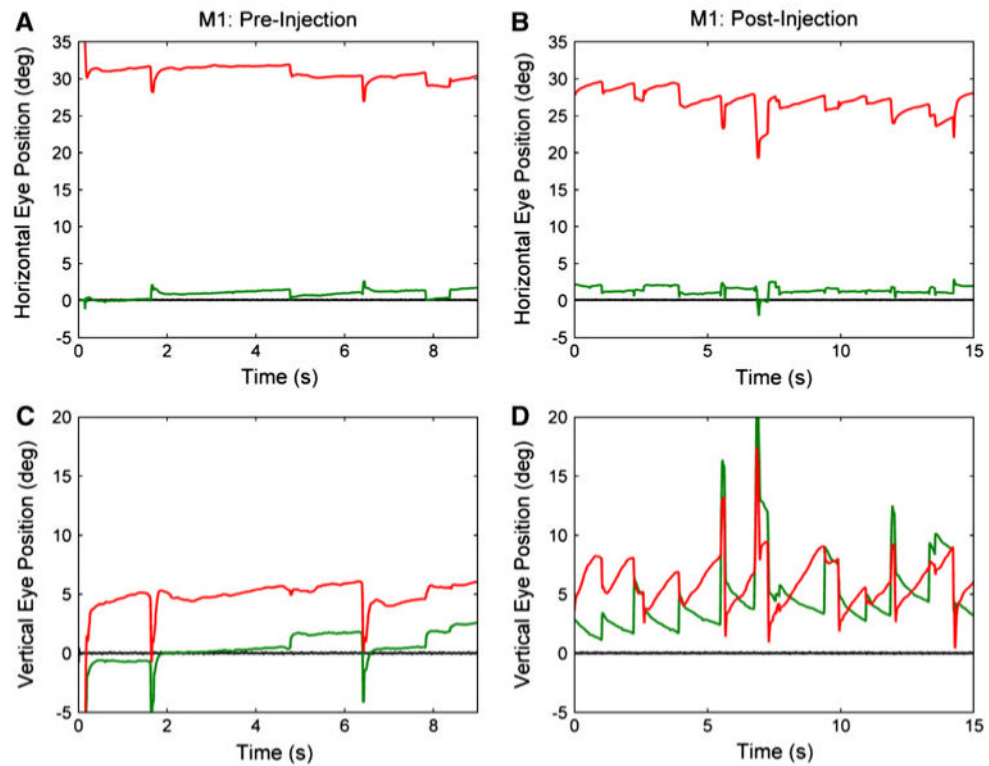


Fig. 2. Hemi-SSN following muscimol injection in animal M1. *Panels a* and *c* show pre-injection fixation data, while *panels b* and *d* show post-injection data. *Panels a* and *b* show horizontal eye positions, while *c* and *d* show vertical eye position. *Panel d* (post-injection vertical eye position) shows the hemi-SSN. The vertical component is down-beating in the right eye and up-beating in the left. *Panel b* shows that there is a small associated right-beating nystagmus. Note that, because the animal is strabismic, there is a horizontal and vertical misalignment observed in the pre- and post-injection conditions. The vertical misalignment appears greater in the post-injection compared to the pre-injection condition, suggesting a superimposed skew deviation. Legend (for all figures): right eye—red; left eye—green; target—black. Rightward and upward eye movements are positive

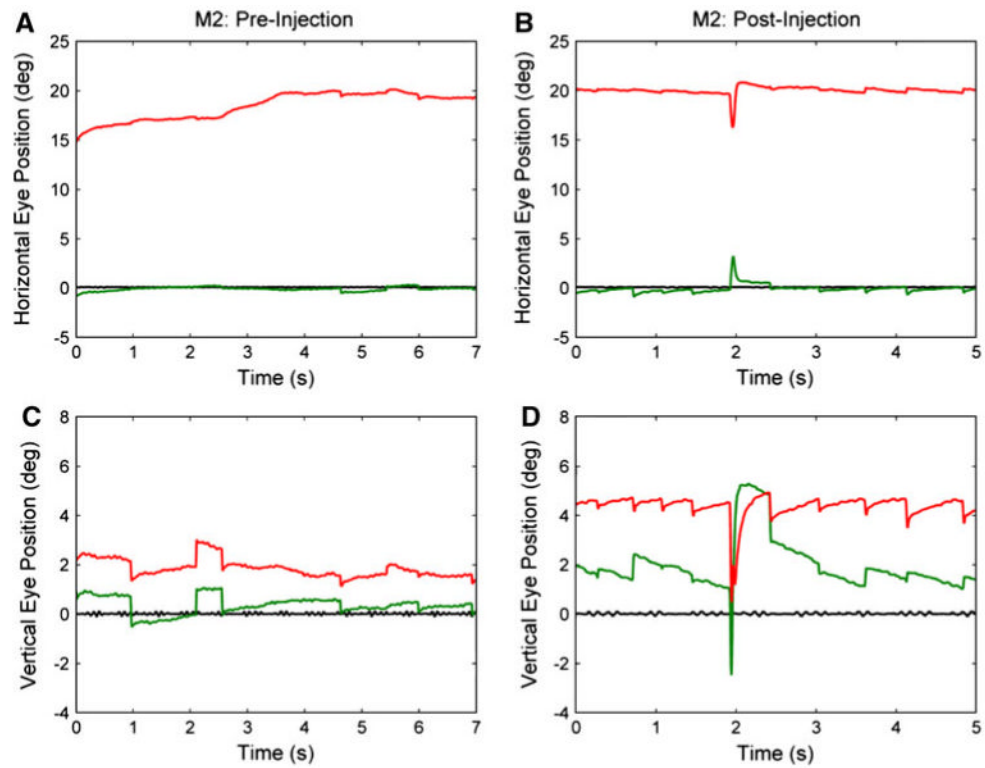


Fig. 3. Hemi-SSN following muscimol injection in animal M2. Panel **d** shows the hemi-SSN. As in animal M1, the vertical component of the hemi-SSN is down-beating in the right eye and up-beating in the left. Unlike in M1 (Fig. 2), the horizontal component is divergent

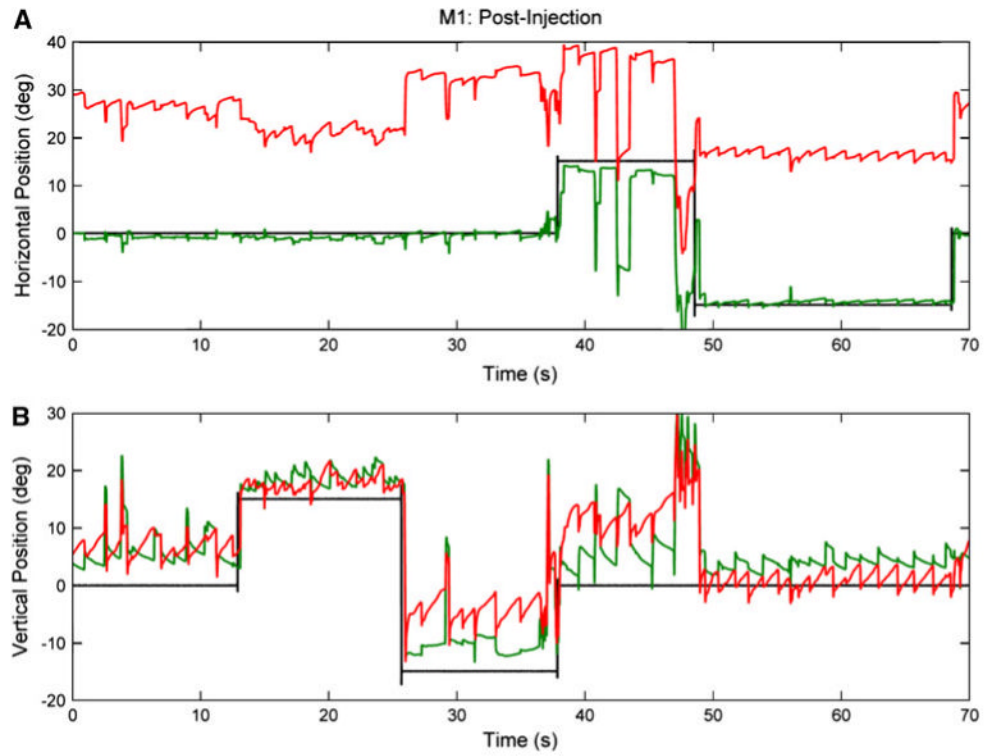


Fig. 4.

Gaze-related changes in hemi-SSN in animal M1. Animal M1 was still able to make horizontal and vertical eye movements in the presence of hemi-SSN, suggesting that the OMN was not compromised when the hemi-SSN first developed. Frequency of hemi-SSN is increased with upward gaze and decreased with downward gaze, with the left eye showing less disjunctive drifts, compared to central viewing. Frequency changes with changes in horizontal eye position were small

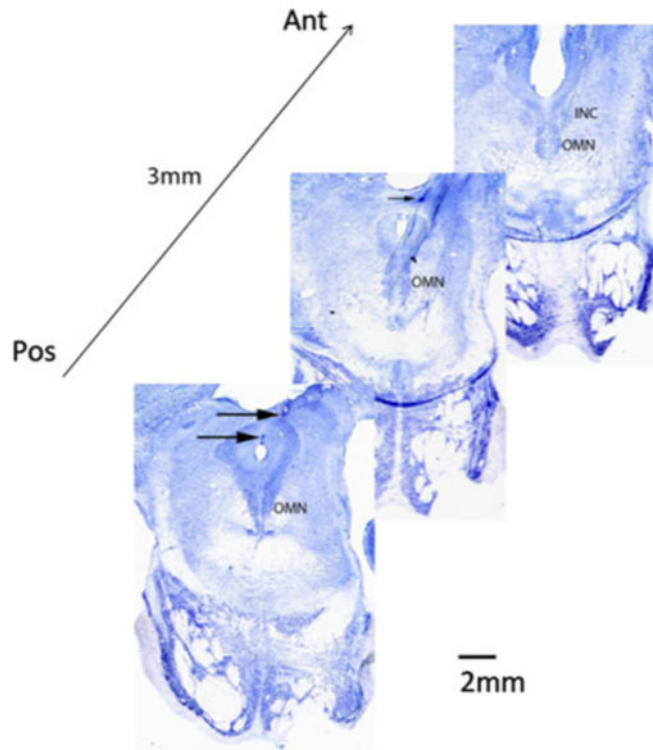


Fig. 5. Histological reconstruction of injection locations. Figure shows three coronal sections, each 1.5 mm apart, through the brainstem. The OMN is visible in all sections, but the INC is only visible in the most rostral section and not in the caudal two sections. Remnants of the electrode tracks and injection pipettes were histologically visible and are shown by the *dotted black lines*. The locations of the electrolytic lesions are visible in the posterior two sections (shown by the *black arrows*). The *middle section* shows only the topmost electrolytic lesion. Motoneurons were recorded approximately 4 mm below this lesion site, while injections were delivered approximately 2 mm below this site. From this reconstruction, the muscimol injections were probably delivered just caudal to the INC and dorsal/dorsolateral to the OMN